

## POLYPS AS BIOMARKERS FOR COLORECTAL NEOPLASIA

M. Tobi

John D. Dingell Veterans Administration Medical Center, and Wayne State University School of Medicine, Detroit, Michigan

### TABLE OF CONTENTS

1. Abstract
2. Introduction
3. Types of colorectal polyps
  - 3.1. Hyperplastic polyps
  - 3.2. Hamartomatous polyps
    - 3.2.1. Peutz-Jeghers Syndrome
    - 3.2.2. Juvenile polyposis
  - 3.3. Adenomatous polyps
    - 3.3.1. Flat adenomas
    - 3.3.2. Adenomatous polyposis coli
    - 3.3.3. The microadenoma
4. Hypersecretory states associated with polyps
5. Monoclonal antibodies against colonic polyps
6. Apoptosis in polyps
7. Modifier of polyp growth and number
8. Perspective
9. Acknowledgments
10. References

### 1. ABSTRACT

Current understanding of colorectal carcinogenesis suggests a series of genetic changes occurring *pari passu* with morphological changes ultimately resulting in a cancerous lesion. The adenomatous polyp was originally the prototype of the preneoplastic lesion but recently, other colonic polyps, primarily the hamartomas, have been clinically characterized as colorectal cancer biomarkers with genetic changes found mainly in the mesenchymal component as opposed to the ectodermal, or epithelial element. This, with the current interest in angiogenesis playing a role in the propagation of neoplastic lesions, has now encompassed every tissue element and opened the way for an understanding of the oncogenic process. This has suggested that considerable interaction occurs between all tissue elements, including what was previously described as epithelial-matrix interactions. While hyperplastic polyps are thought not to confer risk for cancer, they may offer clues as to the first steps of the overall process. Microadenomas have introduced new clinical as well as biological considerations, as unique risk factors. Investigation of these lesions has moved from purely morphological correlations to mechanistic dissections of important biological pathways using both genetic and protein chemistry tools. This review explores the microcosm of the colonic polyp and its relation to cancer as the quintessential premalignant biomarker.

### 2. INTRODUCTION

Much scientific effort has been directed at aberrations of normal chemical pathways as a cause of colon cancer (1-3). The discovery of viral induced cancers

(4) at the beginning of this century opened the way for increasingly sophisticated studies with the advent of molecular genetic tools. Much of this effort had been directed at the cancerous tissue, usually contrasting findings to the adjacent "normal" epithelium (5). While initially useful, this approach may obscure early changes of carcinogenesis and may also include tissues that may not be truly neoplastic. These techniques were later improved and micro-dissection (1) was used to obviate the latter problem. Once the accumulated genetic aberrations had been determined in the micro-dissected cancerous tissue, attention turned to the precursor lesions, adenomatous polyps, where a gradation of these changes was seen from diminutive (<0.5cm) to large polyps (>1cm diameter). This step-wise accumulation of genetic defects is conceptually useful and fits in well with the knowledge gained from animal models of carcinogenesis. However, adenomas develop in a particular environment, and the condition of the mucosa which gives rise to polyps that later develop into cancers is not well understood.

Protein immunohistochemists had been impressed with the altered geographic expression of antigens in the colon (5). Often, in the patient with cancer, this expression was ectopic and sometimes incompatible with the patient's usual antigenic determinants as in the case of blood group antigens (6). The finding of a microscopic equivalent of an adenoma-dysplasia, the aberrant crypt focus, within normal-appearing mucosa suggested that there was a basis for a "field" theory of carcinogenesis (7) and that the study of antigens of the more easily recognizable adenomatous polyps may facilitate our understanding of colorectal cancer (CRC).

## Benign lesions as colon cancer precursors

**Table 1.** Germ Line Genetic Changes in Colorectal Carcinogenesis (after Kinzler and Vogelstein)

Gene Category	Adenoma	Hamartoma	Carcinoma
Gatekeeper (susceptibility)	APC, p53 (late)	STK11 19p13.3	APC, p53
Caretaker (repair)	?	?	ATM, MSH2, MLH1
Landscaper	?	PTEN/SMAD4*; <sup>?</sup> 10q22	?

\*Patients with juvenile polyps are a heterogeneous group, only some of those affected manifest this germ line aberration. Most of the patients grouped under various syndromes have a yet undefined mutation on the long arm of chromosome 10 found in stromal cells.

While a great deal of work with tissue antigens included such polyp tissues (8), surprisingly little effort was directed at raising antibodies specific to adenomas (7,9).

A recent review (10) defined the term biomarker as “a generic term for the targets of assays that monitor critical aspects of the relevant tumor biology in a defined system”. In this sense, apart from its precursor role as an intermediate endpoint biomarker, the polyp may be a marker reflective of the risk for CRC elsewhere in the colon by virtue of the alterations of proliferation, differentiation and genetics which it demonstrates. The intriguing other side of the coin is that the vast majority of polyps do not progress to cancer, and this may teach us much about cancer prevention and give us the power to intervene in the carcinogenic process. Clinically there is much evidence for the fact that the adenomatous polyp is a strong risk factor within families, often as powerful a predictor as the presence of familial CRC itself (11).

Until recently, the adenomatous polyps would have stood unopposed as the archetypal CRC biomarkers. The findings of genetic markers specific for hamartomatous polyps of the familial syndromes of juvenile polyposis (12-15) and Peutz Jegher Syndromes (16), conditions associated with considerable CRC risk, suggests that other complementary pathways exist through which neoplasia may progress. The genetic aberrations in these syndromes abide not in the epithelial component, but in the mesenchymal tissue, suggesting some biochemical “cross-talk” between the epithelial component and the matrix (17,18), long-recognized but heretofore ill-defined. These findings have ushered in the concept of “landscaper” genes (15) which may prepare the milieu for progress of the carcinogenic process (table 1).

Even the hyperplastic polyps, long thought to be irrelevant to carcinogenesis, have been touted in the recent past as a CRC risk marker. Other disturbances of proliferation, manifesting in the skin and other tissue, may confer increased cancer risk (19, 20), suggesting that growth factors may affect widely diverse tissue types.

Clinically, it is possible to significantly reduce the number of adenomatous polyps in adenomatous polyposis coli (APC) patients using cyclooxygenase 2 (COX-2) inhibitors such as sulindac (10). This provides an opportunity to study the changes associated with polyp regression *in-vivo* to and design primary interventions in the prevention of colorectal neoplasia (21). Inhibition of

COX-2 results in apoptosis, which calls into play a number of factors and proto-oncogenes involved in the process of programmed cell-death (10).

Recently, the murine intestinal neoplasia animal model (the *min* mouse) was postulated to have a modifier of *min* (MOM) governing the number of polyps in these genetically engineered rodents (22). The candidate for MOM is phospholipase A2 (PLA2), a constituent of Paneth cells, one of the cellular constituents of polyps (23).

It can be seen from a perusal of the literature that there is scarcely a biochemical pathway in vogue for carcinogenesis, that does not find expression in the colonic polyp. As a precursor of cancer, it may provide clues to complete understanding of carcinogenesis as well as the knowledge to abrogate the disease. For this reason, this review is devoted to the colonic polyp as the biomarker of CRC.

### 3. TYPES OF COLONIC POLYPS

For the purposes of this review, all polypoid lesions associated with submucosal, epithelial neuroendocrine tumors, tumors of neuronal origin (neurofibromatosis associated and others), and inflammatory polyps (despite rare case reports of CRC occurring in the Cronkhite-Canada syndrome), will be excluded. Lymphoid polyposis has been described in the context of APC (24) but will not be included in the review.

A polyp is a projection of a growth into the lumen of the colon. Within the confines of this review, the entities of non-neoplastic and neoplastic polyps will be considered both for their role as precursor lesions as well as biomarkers for CRC risk.

#### 3.1. Hyperplastic Polyps

These common non-neoplastic, polypoid proliferations tend to be sessile and small, occurring in the rectosigmoid as a function of age (25). Morphologically they show a star-shaped crypt or serrated appearance depending on the angle at which they are cut. All cell lineages, including Paneth cells are represented with often prominent muscularis mucosa that may extend up between the glands, but proliferation is normal. These polyps display antigens characteristic of both normal and neoplastic lesions which has suggested to some that this seemingly biologically innocuous lesion may, in some way, constitute a biomarker for CRC elsewhere in the colon.

## Benign lesions as colon cancer precursors

Not all hyperplastic polyps are created equal and the variants of this common type suggest that they are a heterogeneous group yet to be comprehensively classified. This may explain some of the past controversy surrounding their past designation by some as a marker for risk of neoplasia. Currently, 3 variants are recognized: the “large” hyperplastic polyp; the admixed hyperplastic/adenomatous polyp; and the combined or “serrated” hyperplastic/dysplastic polyp (25). The first variant is not thought to have intrinsic neoplastic potential but it is liable to be misdiagnosed as a hamartoma or even as an adenoma with pseudoinvasion. Insufficient data on antigen expression or genetic alterations exist to define its biomarker status.

The two remaining variants (admixed and combined polyps), are substantially different. The adenomatous component is unmistakable and has inherent intrinsic cancer risk. While this risk may be limited in small admixed polyps, the risk in the serrated variant is considerable, with 20% showing morphological changes of intramucosal cancer (25). With respect to their role as biomarkers for CRC risk elsewhere in the colon, the situation is unclear. When such polyps occur in the setting of hereditary non-polyposis colon cancer (HNPCC), microsatellite instability has been described (26). The serrated lesions, with their propensity for high-grade dysplasia, are relatively rare, constituting approximately 0.05% of all polyps (25), making large scale studies impractical. On the other hand, the admixed polyps are far more common but the diagnostic variation is considerable and this group, once appropriately stratified, is therefore a better potential study population.

Few studies have systematically probed genetic differences between hyperplastic and dysplastic polyps. One such study showed no differences in *k-ras* mutations in either type but found no *APC* mutations in small hyperplastic polyps as compared to adenomatous polyps (27). Another sub-variant is multiple hyperplastic polyposis, a rare entity, which is not thought to have neoplastic potential (28). This is in contrast to the variant of serrated adenomatous polyposis where 4/6 patients had associated cancer. This entity displays no distinct immunohistology as compared to the common sporadic polyp (29).

Since hyperplastic polyp subvariants may render this patient population heterogeneous, the available data, including these that refute or uphold the hyperplastic polyp as a biomarker for CRC risk, need to be revisited and carefully reclassified, using strict morphologic criteria. Currently, most authorities do not recognize the classical hyperplastic polyp as a risk marker.

### 3.2. Hamartomatous Polyps

Like the hyperplastic polyp, the hamartomatous polyp is constituted of the normal tissue elements found in the colonic mucosa with differences in proportion, distribution and overall composition. These polyps, either sporadic or familial, often came to light through complications such as bleeding, obstruction, or auto-

amputation and in themselves have limited inherent malignant potential. Over time it was found that certain gastrointestinal cancer occurred in excess, particularly in the familial variants, which suggested a definable genetic basis. Recently a number of candidate genes has been found in these latter disorders which will be described below, focusing on their role as biomarkers for CRC risk. Certain hamartomas such as occur in Cowden syndrome will not be discussed since they have no malignant potential or role as biomarkers for CRC (25).

#### 3.2.1. Peutz-Jeghers Polyp

These lesions can occur throughout the gut primarily in the colon and small intestine. The Peutz-Jeghers polyps are a constituent of an autosomal dominant syndrome linked to a germline mutation on the telomeric end of chromosome 19p (16). There is extraintestinal involvement, often resulting in ovarian, lung and breast neoplasia associated with mucocutaneous melanin ephelides (freckles), which often fade with age. The syndrome was described in 1949 and is relatively rare (~1:20,000) and consequently the direct malignant transformation of these polyps resulting in CRC and other gastrointestinal cancers was not immediately obvious. It is now established that adenomatous or cancerous change occurs within these polyps at 3-6% per year (30). The overall associated incidence of gut malignancy varies between 2-27% (31) with one study showing that 6% actually originated in hamartomatous polyps (32).

The hallmark of this polyp is the presence of dominant smooth muscle bundles. All cell lineages are represented in the epithelial component. In colonic hamartomatous polyps the crypt epithelium may resemble the hyperplastic-polyp type (25). Recognizable adenomatous changes occur on the polyp surface. Other changes include cystic formation which may be extensive and, along with the above features, may be misdiagnosed as cancer. Immunohistochemical data are few, but one study investigating codon 12 *k-ras* mutations found only one of four dysplastic polyps containing the mutation out of 52 total polyps examined (33).

The implicated locus on 19p13.3 is associated with deletions/inversions the LKB1 or STK11 protein alleles which function to encode serine threonine protein kinases, thus resulting in disruption of the kinase domain (34). This domain is important for control of cell proliferation events. In a recent study of 20 families, this linkage was present in 85% (35) suggesting that in a small but significant percentage of families, other gene loci residing close by at 19p13.4 (or elsewhere) in one of 6 families (36) may be responsible for the phenotypic manifestations. This genetic alteration, the first described in a protein kinase conferring cancer susceptibility (37), may provide fertile ground for unopposed proliferation, awaiting further mutations to accumulate, resulting in a neoplastic phenotype. This sequence has not yet been confirmed for these polyps due to the paucity of tissue from colonic polyps with established adenomatous change but the rare presence of mutations known to be associated with

## Benign lesions as colon cancer precursors

**Table 2.** Percentage Somatic Changes in Colonic Polyp

Type	Dysplasia	APC	K-ras	DCC	p53 pr	p21Waf1	Reference
Hyperplastic	rare	0	as for ad\$		rarely	?	28,58,59
Peutz-Jeghers	occasional	?	≤2	?	5-10 <sup>^</sup>	?	25,94,95
Juvenile-sporadic	0	0	14	?	?	8	60
Juvenile-syndromic	31	50	14	?	8*	79loss*	60
Microadenoma	some	5 more dys <sup>+</sup>	13;50-73	?	?	?	61
Adenoma-sporadic	100	~63	67	≤50#	20-40#	75	56,63-5
Flat adenomasHNPCC	100	?	21;0-8	?	?	80	64
Adenoma-APC	100	germline	~20	20-75	0	?	55-6,59,66
Cancer-sporadic	100	~60	~50	23-70	22-85	31	62,65,67-8
Cancer HNPCC	100	?	?	?	27	80	64

p53-pr=overexpression of p53 protein by immunohistochemistry;\$-adenomas;\*-in dysplastic (dys) polyps vs 8% if non-dysplastic; <sup>+</sup>dys=dysplasia; #-in large adenomas, rarely altered in small;@ absent in HNPCC syndromes; ^=cancer.

adenomas, such as *K-ras* (please see table 2), suggests that some other basis for progression of carcinogenesis, in concert with the underlying chromosome 19 mutation, may exist.

### 3.2.2. Juvenile Polyps

This type of hamartoma occurs most often in ~1% of children as the sporadic entity (12,25) often presenting with the aforementioned symptoms common to hamartomatous polyps, particularly bleeding. The rectum is the most common site, and the polyps are usually pedunculated consisting of dilated, cystic fluid-filled spaces in association with inflammation. Hyperplastic features are seen in half but metaplastic changes are less common. Approximately 25% of these polyps are found in adults. While isolated juvenile polyposis carries no predisposition to CRC, in familial juvenile polyposis (>10 polyps) about one fifth of patients will be diagnosed with CRC (38). While the typical juvenile polyp is not felt to have neoplastic potential, some dysplasia can be seen in 10%. If the polyp is “atypical”, there is a fivefold rise in such dysplastic foci (25), which may form the nidus for CRC.

In a third of juvenile polyposis cases an autosomal pattern of inheritance is evident the overall prevalence is unknown, but extremely rare (<1:20,000). There is an increased incidence of CRC among relatives of patients with this condition and this is not seen in the non-familial variant, where affected individuals have also been described to have developed CRC.

Recently 2 groups have described a somatic mutation on chromosome 10q in patients with the familial form (12,13). *In situ* hybridization revealed that the mutation resides in the mesenchymal elements rather than in the ectodermally derived epithelial cells. The subvariants of defined genetic syndromes (Bannayan-Riley-Ruvalcaba/Bannayan-Zonana/ Ruvalcaba-Myhre-Smith Syndrome, Cowden Syndrome) bearing this mutation are a subset of a larger heterogenous group in which other genes may be affected. The loci in the region of 10q23 encode for a protein tyrosine phosphatase, PTEN, which bears homology to a tumor suppressor gene, tensin (39). Another group, who previously were unable to confirm linkage to 10q in 8 informative juvenile polyposis families, has shown

that a germline chromosome 18q21.1 mutation exists in the same genetic segment as the deleted in colon cancer gene (DCC) and the SMAD4/DTC genes. The latter respond to signals from the TGF-beta family of ligands (15), important in the control of proliferation, particularly for mesenchymal elements. This level of control calls into play the “landscaper genes” (table 1) which prepare fertile ground for unrestrained cell proliferation which, in turn, enhances the chance for further genetic alterations that may ultimately contribute to the rise of CRC.

At the somatic level, one study explored the genetic alterations typical of the adenoma-cancer sequence in juvenile polyposis syndrome and compared these to its sporadic juvenile polyp counterpart (40). Almost a third of the syndromic polyps exclusively showed dysplastic changes, with a tenfold loss of the cyclin dependent kinase inhibitor WAF1/CIP1, in syndromic versus sporadic polyps. APC gene mutations were exclusively seen in half the dysplastic polyps, but similar mutations in *K-ras* were seen in 14% of both types. Expression of p53 occurred rarely in the dysplastic polyps (8%). Although the overall numbers were small, this study offers some important insights into the multiple genetic changes involved in the neoplastic transformation of hamartomatous polyps in the juvenile polyposis syndrome.

### 3.3. Adenomatous Polyps

In contrast to hyperplastic and hamartomatous polyps, the adenomatous polyp is a well-accepted fellow-traveler of CRC. Substantial epidemiological and direct clinical observation support its pivotal role as a precursor lesion for CRC. This notwithstanding, there are many unanswered questions regarding the steps from hyperproliferation to neoplasia, and why only a small minority of adenomas progress to cancer remains a subject of constant scrutiny.

Depending on their architecture of either tubular glands or finger-like projections (villi), adenomatous polyps are divided into three entities with some overlap. If an adenoma consists of one predominant architectural form >75% then it is designated either a tubular or a villous adenoma. If a combination of the forms are represented it is designated a tubulovillous adenoma (>25% of each type). These are premalignant lesions and the inherent risk of

## Benign lesions as colon cancer precursors

malignancy is dependent upon architectural type from 5% (tubular) up to 50% (villous) with tubulovillous intermediate depending on the size of the lesions. The degree of differentiation is also important but primarily for the clinical management of the individual polyp. This and other aspects will not be emphasized in this review and the different forms of adenomatous polyps will be individually discussed only in terms of changes associated with the adenoma-carcinoma sequence.

Adenomas are extremely common in the adult population in the Western World (60%) preceding the noted increased incidence of CRC after age 50 by a decade. The vast majority are tubular adenomas (~95%) depending on the type of study (post-mortem versus endoscopic), tend to be small (<1cm), and are distributed throughout the colon, but larger lesions are predominantly left-sided (25). Endoscopically, adenomas may be flat, sessile or pedunculated and cellular features of dysplasia are common to all architectural types with all cell lineages represented by IHC criteria (23). The dysplasia is characterized by mucin depletion, altered nuclear to cytoplasm ratio, palisading of nuclei, increased mitotic figures. Metaplasia is common, particularly of Paneth-cells. Molecular studies are summarized in table 2.

### 3.3.1. Flat adenomas

Flat adenomas may exhibit an accelerated adenoma-carcinoma sequence as when associated with hereditary non-polyposis colorectal cancer (HNPCC) syndrome along with its sub-variant (Torre-Muir Syndrome), and consequently, tend to display features of high-grade dysplasia even when small (41). The depressed flat adenomas differ from their larger polypoid counterpart in the lack of K-ras mutations (42). These polyps may display aberrations in the mismatch repair genes resulting in truncations and decreased activity of the enzymes responsible for repair (table 1) of replicative errors, resulting in microsatellite instability(19). Up to 15% of sporadic tumors may also show this phenotype (43). Recently, an intimate relationship has been shown between tumors with replication errors and mutated genes for the TGF-beta II receptor which normally functions to control growth (44).

Generally speaking, with a few notable exceptions, adenomas display most of the tissue antigens found in cancers and have rarely been of use in clinical differentiation (45). Many of these are also expressed in normal-appearing epithelium with mainly quantitative differences. The more useful antigenic changes described may be related to known genotypic changes, hence the loss of expression of adhesion molecules such as E-cadherin and its associated proteins such as the catenins and p180. Their reduction of expression from ~100% in normal mucosa and hyperplastic polyps to only 65% in adenomas, reflects the early and important changes in carcinogenesis (46). The genetic aberrations which accumulate with progression of the adenoma-carcinoma sequence appear to be far more relevant and will be discussed below.

Recently, a prospective study of adenomatous polyps of <1cm left *in situ* for 3 years, found that, while

diminutive polyps (<0.5mm) tend to grow, small polyps (0.5 to 0.9cm) tend to regress (47). This may explain why in APC, out of many thousands of polyps, only a small number of cancers develop. There is also a discrepancy between the number of sporadic adenomas and the number of invasive cancers but this regression of polyps is not sufficient to explain this phenomenon. There may be other explanations that may be relevant and these will be explored below.

### 3.3.2. Adenomatous Polyposis Coli

This condition, seen in about 1:8,000 of the population and constituting <1% of cases with CRC, is the archetypal condition reflecting the consequences of the adenoma-carcinoma sequence, with almost 100% penetrance. It is an autosomal dominant disorder caused by a germline mutation of chromosome 5q resulting in a mutation in a large gene encoding a structural adhesion protein called the APC protein which in its normal form binds to beta-catenin and other cadherin-related proteins serving as a linker to the actin cytoskeleton. Beta-catenin is stabilized by the Wnt-1 pathway via glycogen synthase kinase-3 beta (GSK). Normally APC and GSK induce beta catenin breakdown. Tyrosine phosphorylation of beta-catenin in neoplastic transformation occurs with a reduction in cell adhesion and differentiation. The final steps in the path to invasive cancer have yet to be elucidated (48). At the somatic level, it appears that APC mutations occurs in ~20% of sporadic polyps as well and occurs at an early stage of carcinogenesis. In APC, every somatic cell is already primed with this mutation so that the overall process of genetic aberration is well underway by early adulthood with 90% of cancers detected by 45 years of age. Mutations vary depending on the location of the mutation within the APC gene (48). Once the truncating mutation in an affected family is identified (~80%), the *in-vitro* synthesized protein (IVSP) test is informative for that family. Almost 20% of cases represent new mutations and there is no family history. Genetic counseling to ensure adequate patient education before testing is paramount (49). While genetic testing is important, the mainstay for the detection of non-attenuated forms of APC is flexible sigmoidoscopy starting at puberty to look for the quintessential biomarker and hallmark of this condition, the adenomatous polyp. Numerous other extra-intestinal sites for carcinoma occur in APC such as the brain (Turcot's Syndrome), the thyroid, adrenals etc., for which the clinician should maintain a low threshold of suspicion.

While colectomy and ablation of duodenal adenomas and desmoid tumors are the bedrock of management for APC patients once identified, certain interventions have been adopted to cause regression of residual adenomas. Prominent in these efforts have been non-steroidal anti-inflammatory drugs (NSAID), some of which significantly inhibit activity of the COX-2 enzyme and diverts arachidonic acid metabolism from formation of prostaglandins (PG) to 15-HETE, which has antimutagenic action (10). Other potential modes of action include: reduction of E series PG affecting tumor growth; decreased generation of oxygen radicals and malondialdehyde, a

## Benign lesions as colon cancer precursors

powerful mutagen; NSAID suppression of the distal promoter of COX-2; suppression of NF- $\kappa$ B transcription factor; and the modulation of apoptosis, partially through cyclin dependent kinase reduction; as well as interleukin, interferon and tumor necrosis factor- $\alpha$ .

COX-2 is an inducible enzyme and is inhibited by sulindac through independent action of its sulfide and sulfone metabolites, and has caused substantial regression in the size and number of adenomas in intact colons of APC patients (50). However, polyps recur if the drug is discontinued. A similar regression has also been described in the APC patient's residual colon stump after colectomy. The major question is: if the biomarker regresses, does the risk for CRC diminish? Thus far this question has been difficult to answer. Two case reports documented the occurrence of CRC in the rectal remnant after colectomy despite sulindac treatment and close endoscopic surveillance (51,52). Sulindac has also yet to be proved effective in polyp regression in the setting of sporadic adenomas. What is needed is a reliable marker for cancer risk and a gauge of how much COX-2 activity is suppressed by conventional dosing. With the recently developed new specific COX-2 inhibitors that may be administered long-term, it is hoped that the means of chemical eradication of adenomas can be improved. While the future is optimistic there are considerable potential obstacles to be overcome.

The preceding sections have covered the familial polyposis syndromes and the corresponding germ line mutations which are categorized in table 1.

### 3.3.3. The microadenoma

A decade ago researchers working with a common murine model of carcinogenesis noticed microscopic adenomas in the normal appearing mucosa manifesting as aberrant crypts and these lesions have since been described in human colonic mucosa recently shown to be a risk marker for CRC (53). These foci can express many of the oncofetal cancer antigens such as CEA (54). In the former study, there was a high prevalence of *k-ras* mutations (up to 92%) but as the foci became more dysplastic, the prevalence was reduced to 57% (53). The authors suggested that this alteration is not involved in the formation of the progressive lesion. This would imply that the sequence is altered from the generally accepted model (1), where this mutation is found mainly in the larger adenomas. It may, however, explain our findings of *k-ras* mutations in the colonic effluent of patients at risk for CRC but without detectable neoplasia at colonoscopy (55). Foci were not found in 12% of adenoma patients where most of these adenomas were right sided, suggesting an alternative for carcinogenesis as has been defined in right-sided cancers with RER microsatellite changes (53). It is thought that most larger aberrant crypt foci, particularly if heteroplastic (57), are not neoplastic and it appears that the more dysplastic they are, the more likely they are to show the APC mutation (56). Furthermore, ACF from colons of APC patients are liable to show more dysplasia and stain with lectins and CA19-9, but show little tendency to K-ras

mutations (57). The number of foci could also be reduced by the administration of sulindac resulting in the disappearance from almost 2/3 of the treated patients (10). For further data and references on microadenomas, see the summary in table 2.

## 4. HYPERSECRETORY STATES ASSOCIATED WITH POLYPS

Some of the genetic changes enumerated in table 1 may provide a fertile environment for proliferation of neoplastic polyps. If some of these underlying changes have occurred in the mucosa at risk it is possible that in a macro-environment conducive to accelerated growth, these lesions may develop. Acromegaly is a condition associated with increased circulation levels of growth hormone and insulin-like growth factors and is associated with excess colonic neoplasia, both cancerous and adenomatous (69-72). Only one of these studies was a prospective case control study (72). However, this association is generally accepted.

Another example of a hypersecretory state is hypergastrinemia, usually seen in its most extreme form in the Zollinger-Ellison Syndrome where a gastrinoma, a rare neuroendocrine tumor, secretes biologically active gastrin which has trophic effects on the gut. The association of this syndrome is controversial but we have recently reported several new cases as well as reviewed the literature and documented 34 such cases (20). Most neoplasms were polyps [n=27] but 7 had CRC and one prospective study showed a potential prevalence of 8.6% for cancer and 17% for adenomas (73). While some data from uncontrolled trials show no increase in colorectal neoplasia, further studies are needed to confirm an association (20).

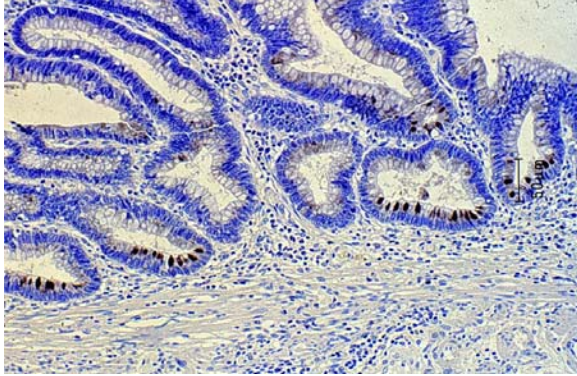
Another condition associated with increased numbers of premalignant adenomatous polyps, is in the colon after uterosigmoidostomy for urinary diversion. All forms of polyps have been described and while latency periods may be as long as 20 years, abbreviated instances of as short as 4 months lead to concern and the need for endoscopic surveillance (74). This suggests that constant exposure of the bowel to nitrosamines (produced by gut flora action on urinary amines) might be a promoting factor.

Another condition may be breast cancer, where some of the risk factors with colorectal cancer are shared. Lastly, low somatostatin levels might also predispose to adenomas as this anti-proliferative hormone has been suggested to be protective against colorectal neoplasia (75). However, this will need to be confirmed by further study.

## 5. MONOCLONAL ANTIBODIES RAISED AGAINST COLONIC POLYPS

Given the profusion of monoclonal antibodies raised against constituents of CRC (76), it is surprising that few attempts were made using constituents of adenomas. Part of the reason is that, generally speaking, almost every cancer associated antigen described can be found in

## Benign lesions as colon cancer precursors



**Figure 1.** Adnab Staining of Paneth Cells in an Adenoma. This Adnab immunohistochemical photomicrograph shows intense staining in the cytoplasm of multiple triangular shaped cells at the base of dysplastic glands in a adenomatous polyp. The substrate is diaminobenzidine and the scale is shown by a bar insert.

adenomas and even normal mucosa and benign hyperplastic polyps, with usually only quantitative differences. The first attempt to use adenoma as immunogen was reported in 1983 and resulted in a blood group determinant that was present in adenoma and cancer (9) and thus had little differential utility.

In 1990 we reported the generation of monoclonal antibodies against constituents of tubular adenomas in an attempt to define the earliest possible manifestation of an adenoma associated antigen (7). Part of the hybridoma screening strategy was to exclude common oncofetal and other cancer antigens. The antibody selected for its diagnostic utility was designated Adnab-9. The antigen has been partially characterized as a 87kDa 10% N-linked glycoprotein (77). The antibody displays differential binding to adenomas and appears to recognize a subset of cells deep within the substance of the adenoma (78). Subsequently, some of these cells have been identified as Paneth-like cells (figure 1) in tissues with or at risk for CRC (79). Paneth cells in APC patients have been shown to secrete epidermal growth factor (80), a ligand for a receptor that, once activated, is mediated by tyrosine kinase. Preliminary data has been accrued showing reactivity in mucosa harboring and at risk for CRC, including acromegaly and ZES (20). Once identified, the gene encoding the gp87 antigen might provide important insights into early carcinogenesis.

## 6. APOPTOSIS IN POLYPS

As has been discussed above, there appears to be an important pathway by which most polyps regress with only 5% estimated to progress to larger lesions and CRC (81). This implies that in sporadic neoplasia without a germ line defect, even the accumulation of some of the early genetic changes in carcinogenesis is not sufficient to override the tendency to regress. The ability to harness this seemingly natural phenomenon might allow primary prevention strategies to be devised and to realize substantial savings from colonoscopic polypectomy. To date, this

invasive procedure appears the only effective way to reduce CRC incidence by adenoma detection and removal (82), although better controlled studies are needed to confirm this. Currently effects are underway to achieve this using COX-2 inhibitors and vitamins, including folate acid (83). The surrogate end-point in these studies may be reduced polyp detection but the true endpoint will be reduction of CRC mortality.

The current COX-2 inhibitors in clinical use, which also inhibit COX-1 to a certain extent, and are thought to operate through the induction of apoptosis, i.e., programmed cell death (see adenomatous polyp section above). Apoptosis has been shown to bear a positive correlation to the various phenotypic stages in the adenoma-carcinoma sequence, being higher in adenoma and APC mucosal cells than in those from carcinoma. Apoptosis appears to be regulated by a variety of mechanisms operating through the expression of *bcl-2* proto-oncogene product, which is inversely related to the degree of apoptosis (84). There appears to be a close relation between the latter and the wild-type p53 which promotes apoptosis, possibly activated through a p53-binding repressor on the promoter of the *bcl-2* gene (85). Generally, the apoptotic index is higher in adenomas of all varieties as compared to CRC. One study did not show a correlation with *bcl-2* expression, but rather with another apoptosis-related protein, *bak* (86). While other investigators also describe a relation between *bcl-2* and *p53* expression (64), some have shown that the altered distribution of *bcl-2* expression can also be seen in hyperplastic polyps but, interestingly, not in hamartomatous polyps (85). The *bcl-2* protein is touted as an early change in the progression of carcinogenesis, but overall the numbers are generally too small to come to any definite conclusions. The other side of the apoptotic coin is the property of immortalization, a characteristic of cancer cells, thought to be related to telomerase expression. A recent study showed that while this is the case in CRC, it appears to be independent of p53 expression (87). There are other determinants of apoptosis such as the *Bax* and *Box* proteins, and *APO-fas* genes, all of which should be examined in concert to determine the cause of the resultant phenotypes.

While the approach to reduce polyp number by chemical means is clinically promising, it appears that CRC can develop in the scenario of sulindac treatment of sporadic adenomas (88) as well as in the context of APC patients (51,52). These developments warrant tempering of the current enthusiasm that exists for this clinical strategy.

## 7. MODIFIER OF POLYP GROWTH AND NUMBER

This concept grew out of the Min mouse animal model for APC in which the mouse APC homologue is inactivated and the mouse develops multiple intestinal neoplasia (Min), primarily of the small intestine. However, the number of polyps that develop depend on the genetic makeup of the mouse and is thought to be governed by a modifier of Min (MOM-1) which is an unlinked modifier of polyp multiplicity and growth (13). The candidate for

## Benign lesions as colon cancer precursors

this mouse model resides on mouse chromosome 4 and encodes a secretory phospholipase (Pla2a) which when overexpressed using a cosmid transgene, caused a decrease in adenoma number and size (89). There is speculation whether such a modifier exists in man and some discount the secretory Pla2a from having a role in the human scenario (90). However, the Pla2a in question is a constituent of Paneth cells (91), which may have a role in the development of small intestinal adenomas in human APC and appear to be the cellular constituent bearing the early adenoma antigen defined by the Adnab-9 monoclonal antibody raised against adenomas. The Pla2a concept also may fit in well with eicosanoid metabolism, for which it may provide a substrate for the COX-2 enzyme (92). The finding that may close the circle on the contribution of the epithelial matrix and the changes in the mucosal milieu, is the recent report linking both COX variants with angiogenesis, with COX-2 modulating angiogenic factor production in colon cancer cells (93). Doubtless, this pathway will be elucidated in the near future, given the present pace of scientific endeavor in this field.

## 8. PERSPECTIVE

The burgeoning field of colorectal tumorigenesis will demand constant updates of any current review, which will be dated by the time it reaches print. The on-line format is thus well suited to updates. While the adenoma-carcinoma sequence hypothesis has its limitations, it is a useful framework for the understanding of colorectal carcinogenesis. There are intriguing hiatuses in our knowledge which will no doubt be filled in the near future. Some hypotheses will have to be borne out by prospective long-term follow-up. The most exciting aspect of this area of scientific endeavor is the translational research for potential intervention at a number of junctures to cause regression of polyps and reduce the risk and, therefore, the mortality from the second major cancer killer in the Western World.

## 9. ACKNOWLEDGMENTS

The author would like to express his thanks to the Research and Medical Media Services of the John D. Dingell VAMC for support and technical assistance respectively, Mark Gesell Ph.D for help with the photomicrograph, Dr. J. Nunez for clinical material, Drs. S. Fligiel, J. Hatfield, J. Moshier, and A. Majumdar for their helpful comments on the manuscript. This review is dedicated to the memory of Mel Katz.

## 9. REFERENCES

1. E.R. Fearon, B. Vogelstein. A genetic model for colorectal tumorigenesis. *Cell*, 61,759-67 (1990)
2. D.W. Hein. Acetylator genotype and arylamine-induced carcinogenesis. *Biochim Biophys Acta* 948,37-66 (1988)
3. G.D. Luk, S.B. Baylin. Ornithine decarboxylase as a biological marker in familial colonic polyposis. *N Engl J Med* 311,80-3 (1984)
4. C.M. Fenoglio, J.H. Lefkowitz. Viruses and cancer. *Med Clin N Am* 67,1105-27 (1983)

5. M. Yuan, S.H. Itzkowitz, A.Palekar et al. Distribution of blood groups A,B,H.Lewis a and Lewis b in human normal, fetal and malignant colonic tissue. *Can Res* 45,4499-511 (1985)
6. S-i. Hakamori. Aberrant glycosylation in tumors and tumor-associated carbohydrate antigens. *Adv Can Res* 52,257-331 (1989)
7. M.Tobi, E. Darmon, T. Philips, et al. Increased expression of a putative adenoma associated antigen in precolonoscopic effluent of patients with colorectal cancer. *Cancer Lett* 50,21-5 (1990)
8. C.R. Boland. Searching for the face of neoplasia. *J Clin Gastro* 10,599-604 (1988)
9. A. Brown, T. Feizi, H.C. Gooi et al. A monoclonal antibody against human colonic adenoma recognizes difucosylated type-2-blood-group chains. *Biosci Rep* 3,163-70 (1983)
10. K. Krishnan, D.E. Brenner. Chemoprevention of colorectal cancer. *Gastro Clin N Am* 25,821-58 (1996)
11. L.A. Cannon-Albright, M.A. Skolnick, D.T. Bishop, R.G. Lee, R.W. Burt, R. Common inheritance of susceptibility to colonic adenomatous polyps and associated colorectal cancers. *N Engl J Med*, 319,533-7 (1988)
12. R.F. Jacoby, S. Schlack, C.C. Cole, M. Skarbek, C. Harris, L.F. Meisner. A juvenile polyposis tumor suppressor gene at 10q22 is deleted from nonepithelial cells in the lamina propria. *Gastroenterology* 112,1398-1403 (1997)
13. A.F. Zigman, J.E. Lavine, M.C. Jones, C.R. Boland, J.M. Carethers. *Gastroenterology* 113,1433-7 (1997)
14. J.R. Howe, S. Roth, J.C. Ringold, R.W. Summers, H.J. Jarvinen, P. Sistonen, I.P.M. Tomlinson, R.S. Houlston, S. Bevan, F.A. Mitros, E.M. Stone, L.A. Aaltonen. Mutations in the SMAD4/DPC4 gene in juvenile polyposis. *Science* 280, 1086-8 (1998)
15. K.W. Kinzler, B. Vogelstein. Landscaping the Cancer Terrain. *Ibid* 1036-7.
16. C.I. Amos, D. Bali, J. T. Thiel, J.P. Anderson, I. Gourley, M.L. Frazier, P.M. Lynch, M.A. Lechtfeld, A. Young, T.J. McGarrity, M.F. Seldin. *Cancer Res* 57,3653-6 (1997)
17. C.M. Fenoglio, G.I. Kaye, R.R. Pascal, N. Lane. Defining the precursor tissue of ordinary large bowel carcinoma, implications for cancer prevention. *Pathol Annu* 12,87-116 (1977)
18. M. Kedinger, O. Lefebvre, I. Duluc, J.N. Freund, P. Simon-Assmann. Cellular and molecular partners involved in gut morphogenesis and differentiation. *Philos Trans R Soc Lond B Biol Sci* 353,847-56 (1998)
19. G. Marra, C.R. Boland. DNA repair and colorectal cancer. *Gastro Clin N Am* 25,755-72 (1996)
20. M. Tobi, A. Cats, B.J. Malliakal, J.L. Kinzie, R. Maliakkal, R.P.F. Dullaart, G.D. Luk. Zollinger-Ellison Syndrome, acromegaly, and colorectal neoplasia. *J Clin Gastroenterol* 24,21-4 (1997)
21. E. Giovannucci, M.J. Stampfer, G.A. Colditz, et al. Multivitamin use, folate, and colon cancer in women in the nurses' health study. *Ann Int Med*, 129,517-24 (1998)
22. K.A. Gould, W.F. Dove. Localized gene action controlling intestinal neoplasia in mice. *Proc Natl Acad Sci* 94,5848 (1997)
23. S.B. Ho, S.H. Itzkowitz, A.M. Frieria, S.H. Jiang, Y.S. Kim. Cell lineage markers in premalignant and malignant colonic mucosa. *Gastroenterology* 97, 392-404 (1989)



## Benign lesions as colon cancer precursors

24. P.S. Venkitachalam, E. Hirsch, A. Elguezabal, L. Littman. Multiple lymphoid polyposis and familial polyposis of the colon: a genetic relationship. *Dis Colon Rectum* 21,336-41 (1978)
25. H S Cooper: Intestinal neoplasms. In: *Diagnostic surgical pathology*. Ed: Sternberg S S, Raven Press, NY (1994)
26. J.R. Jass, D.S. Cottier, V. Pokos, S. Parry, I.M. Winship. Mixed epithelial polyps in association with hereditary non-polyposis colorectal cancer providing an alternative pathway of cancer histogenesis. *Pathology* 29,28-33 (1997)
27. J. Jen, S.M. Powell, N.Papadopoulos, K.J. Smith, S.R. Hamilton, B. Vogelstein, K.W. Kinzler. Molecular determinants of dysplasia in colorectal cancer. *Cancer Res* 54,5623-6 (1994)
28. G.T. Williams, J.F. Arthur, H.J.R. Bussey, B.C. Borson. Metaplastic polyps and polyposis of the colorectum. *Histopathology* 4,155-70 (1980)
29. E. Torlakovic, D.C. Snover. Serrated adenomatous polyposis in humans. *Gastroenterology* 110, 748-55 (1996)
30. T. Narita, T. Eto, T. Ito. Peutz-Jeghers Syndrome with adenomas and adenocarcinoma in colonic polyps. *Am J Surg Path* 11,76-81 (1987)
31. T.M. Giardello, S.B. Welch, S.R. Hamilton, J.H. Offerhaus, G.D. Luk. Increased incidence of cancer in the Peutz-Jeghers Syndrome. *N Engl J Med* 316, 1511-4 (1987)
32. A.D. Spigelman, V. Murday, R.K.S. Phillips. Cancer and the Peutz-Jeghers Syndrome. *Gut* 30,1588-90 (1989)
33. M.M. Entius, A.M. Westerman, F.M. Giardello, et al. Peutz-Jeghers polyps, dysplasia, and K-ras codon 12 mutations. *Gut* 41,320-2 (1997)
34. D.E. Jenne, H.Reimann, J. Nezu, et al. Peutz-Jeghers Syndrome is caused by mutations in a novel serine threonine kinase. *Nature Genetics* 18,38-43 (1998)
35. Olschwang, D. Markie, S. Seal et al. Peutz-Jeghers disease: most, but not all, families are compatible with linkage to 19p13.3. *J Med Genetics* 35,42-4 (1998)
36. H. Mehenni, J.L. Blouin, U. Radhakrishna et al. Peutz-Jeghers Syndrome: confirmation of linkage to chromosome 19p13.3 and identification of a second locus, on 19p13.4. *Am J Med Genetics* 61,1327-34 (1997)
37. A. Hemminki, D. Markie, I. Tomlinson, et al. A serine/threonine kinase gene defective in Peutz-Jeghers Syndrome. *Nature* 391,184-7 (1998)
38. J.R. Jass, C.B. Williams, H.J.R. Bussey, B.C. Morson. Juvenile polyposis-a precancerous condition. *Histopathology* 13,619-30 (1988)
39. H.T. Lynch, E.A. Ostermeyer, M.K. Lee, et al. Inherited mutations in PTEN that are associated with breast cancer, Cowden disease, and juvenile polyposis. *Am J Hum Genetics* 61,1254-60 (1997)
40. T.T. Wu, B. Rezaei, A. Rashid, M.C. Luce, M.C. Cayouette, C. Kim, N. Sani, L. Mishra, C.A. Moskaluk, J.H. Yardley, S.R. Hamilton. Genetic alteration and epithelial dysplasia in juvenile polyposis syndrome and sporadic juvenile polyps. *Am J Path* 150,939-47 (1997)
41. S.J. Lanspa, H.T. Lynch, T.C. Smyrk et al. Colorectal adenomas in the Lynch syndromes. Results of a colonoscopic screening program. *Gastroenterology* 98, 1117-22 (1990)
42. T. Muto, H. Nagawa, T. Watanabe, T. Masaki, T Sawada. Colorectal carcinogenesis: historical review. *Dis Col Rect* 40,880-5 (1997)
43. F.M. Giardello. Genetic testing in hereditary colorectal cancer. *JAMA* 278,1278-81 (1997)
44. S. Markowitz, J. Wilson, M. Brittain, et al. Inactivation of the type II TGF-beta receptor in colon cancer cells with microsatellite instability. *Science* 268,1336-8 (1995)
45. N. Zamcheck, P. Liu, P. Thomas et al. Search for useful biomarkers of pre- or early malignant tumors. In: Steele G, Burt RW, Winawer SJ, Karr JP eds. Basic and clinical perspectives of colorectal cancer and polyps. *Progress in clinical and biological research*. Alan R. Liss, Inc., New York, 279,251-75 (1988)
46. A. Valizadeh, A.J. Karaianakis, I. El-Hariry, W. Kmiot, M. Pignatelli. Expression of E-cadherin-associated molecules (alpha-,beta-, and gamma-catenins and p180) in colorectal polyps. *Am J Path* 150,1977-84 (1997)
47. B. Hofstad, M.H. Vatn, S.N. Andersen, H.S. Huitfeldt, T. Rognum, S. Larsett, M. Osnes. Growth evaluation of colorectal polyps: redetection and evaluation of unresected polyps for a period of three years. *Gut* 39, 449-56 (1996)
48. R.W. Burt. Familial risk and colorectal cancer. *Gastro Clin N Am* 25,793-803 (1996)
49. F.M. Giardello, J.D. Brensinger, G.M. Petersen, et al. The use and interpretation of commercial gene testing for familial adenomatous polyposis. *N Engl J Med* 336,823-7 (1997)
50. F.M. Giardello, S.R. Hamilton, A.J. Krush, et al. Treatment of colonic and rectal adenomas with sulindac familial adenomatous polyposis. *N Engl J Med* 328,1313-6 (1993)
51. A.G. Thorson, H.T. Lynch, T.C. Smyrk. Rectal cancer in FAP patient after sulindac. *Lancet* 343,180 (1994)
52. Y. Niv, G.M. Fraser. Adenocarcinoma in the rectal segment in familial polyposis coli is not prevented by sulindac therapy. *Gastroenterology* 107,854-7 (1994)
53. T. Takayama, S. Katsuki, Y. Takahashi, et al. Aberrant crypt foci of the colon as precursors of adenoma and cancer. *N Engl J Med* 339,1277-84 (1998)
54. T. P. Pretlow, E.V. Roukhadze, M.A. O'Riordan, J.C. Chan, S.B. Armini, T.A. Stellato. Carcinoembryonic antigen in human colonic aberrant crypt foci. *Gastroenterology* 107,1719-25 (1994)
55. M. Tobi, L. Feng-Chi, Z. Ronai. Detection of K-ras mutation in colonic effluent samples from patients without evidence of colorectal carcinoma. *J Natl Cancer Inst* 86,1007-10 (1994)
56. J.M. Carethers. The cellular and molecular pathogenesis of colorectal cancer. *Gastro Clin N Am* 25,737-54 (1996)
57. M.R. Nucci, C.R. Robinson, P. Longo, Campbell, S.R. Hamilton. Phenotypic and genotypic characteristics of aberrant crypt foci in human colorectal mucosa. *Human Path* 28,1396-407 (1997)
58. A. Barletta, F. Marzullo, A. Pellicchia et al. DNA flow cytometry, p53 levels and proliferative cell nuclear antigen in human colon dysplastic, precancerous and cancerous tissues. *Anticancer Res* 18,1677-82 (1998)
59. C.A. Purdie, J. O'Grady, J. Piris, A.H. Wyllie, C.C. Bird. P53 expression in colorectal tumors. *Am J Path* 138, 807-13 (1991)
60. T.T. Wu, B. Rezaei, A. Rashid, et al. Genetic alterations and epithelial dysplasia in juvenile polyposis syndrome and sporadic juvenile polyps. *Am J Path* 150,939-47 (1997)
61. A.J. Smith, H.S. Stern, M. Penner, K. Hay, A. Mitri, B.V. Bapat, S. Gallinger. Somatic APC and K-ras codon 12 mutations in aberrant crypt foci from human colons. *Can Res* 54,5527-30 (1994)
62. T.C. Hoops, P.G. Traber. Molecular pathogenesis of colorectal cancer. *Hem Onc Clin N Am* 11,609-33 (1997)
63. H. Nagawa, S. Yamagata, T. Muto. Precancerous lesion in colorectal cancer (Japanese). *Jap J Can Chemo* 22,2043-7 (1995)
64. F.A. Sinicrope, G. Roddey, M. Lemoine, S. Ruan, L.C. Stephens, M.L. Frazier, Y. Shen, W. Zhang. Loss of p21WAF/Cip1 protein expression accompanies progression of sporadic colorectal neoplasms but not hereditary nonpolyposis colorectal cancers. *Clin Can Res* 4,1251-61 (1998)

## Benign lesions as colon cancer precursors

65. Y. Zhou, D. Zhou, A. Yuan. A study on the changes of DCC and MCC genes in colorectal cancer and adenoma. *Chin J Int Med* 35,444-6 (1996)
66. R. Minami, N. Aoyama, Y. Horsako, M. Kasuga, T. Fujimori, S. Maeda. Codon 201 arg/gly polymorphism of DCC gene in flat- and polypoid-type colorectal tumors. *Dig Dis Sci* 42,2446-52 (1997)
67. A. Levine. Normal and Neoplastic Growth and Development. AACR Special Conference in Cancer Research. *Cancer Res* 53,929-30 (1993)
68. N.J. Froggatt, S.H. Leveson, R.C. Gamer. Low frequency and late occurrence of p53 and DCC aberrations in colorectal tumours. *J Can Res Clin Onc* 121,7-15 (1995)
69. I. Klein, G. Parveen, J.S. Gavalier, D.H. Van Thiel. Colonic polyps in patients with acromegaly. *Ann Int Med* 97,27-30 (1982)
70. A. Pines, P. Rozen, E. Ron, T. Gilat. Gastrointestinal tumors in acromegalic patients. *Am J Gastroenterol* 80,266-7 (1985)
71. J.E. Brunner, C.C. Johnson, S. Zafar, E.L. Peterson, J.F. Brunner, R.C. Mellinger. Colon cancer and polyps in acromegaly: increased risk associated with family history of colon cancer. *Clin Endocrinol* 32,65-71 (1990)
72. S. Ezzat, C. Strom, S. Melmed. Colon polyps in acromegaly. *Ann Int Med* 114,754-5 (1991)
73. I. Sobrani, T. Lethy, P. Laurent-Pugh, G. Cadiot, P. Ruzsniowski, M. Mignon. Chronic hypergastrinemia in humans: evidence for a mitogenic effect on the colonic mucosa. *Gastroenterology* 105,22-30 (1993)
74. D.A. Husmann, H.M. Spence. Current status of tumor of the bowel following uterosigmoidostomy: a review. *J Urol* 144,607-10 (1990)
75. J. Payer Jr, M. Huorka, I. Duris et al. Somatostatin and large bowel polyps. *Hep-gastroenterol* 42,775-7 (1995)
76. D. Solitzeanu. Human cancer-associated antigens: present status and implications for immunodiagnosis. *Adv Can Res* 44,1-41 (1985)
77. M. Tobi, B. Maliakkal, I. Zitron et al. Colonic effluent adenoma associated antigen correlated with colorectal cancer is a membrane-bound glycoprotein. *Cancer Lett* 67,61-69 (1992)
78. M. Tobi, B. Maliakkal, M.A. Alousi et al. Cellular distribution of a colonic adenoma-associated antigen as defined by monoclonal antibody, Adnab-9. *Scan J Gastro* 27,737-42 (1992)
79. M. Tobi, Y. Elitsur, M.P. Moyer, A. Halline, M. Deutsch, L. Nochomovitz, G.D. Luk. Mucosal origin and shedding of an early colonic marker defined by Adnab-9 monoclonal antibody. *Scan J Gastro* 28,1025-34 (1993)
80. S. Bulow, P. Skov Olsen, S.S. Poulsen, P. Kirkegaard. Is epidermal growth factor involved in development of duodenal polyps in familial polyposis coli. *Am J Gastroenterology* 83,404-6 (1988)
81. S.J. Winawer, R.H. Fletcher, L. Miller et al. Colorectal cancer screening: clinical guidelines and rationale. *Gastroenterology* 112,594-642 (1997)
82. S.J. Winawer, A.G. Zauber, M.N. Ho et al. Prevention of colorectal cancer by colonoscopic polypectomy. *N Engl J Med* 329,1977-81 (1993)
83. B.A. Lashner, P.A. Heidenreich, G.I. Su, et al. Effect of folate supplementation on incidence of dysplasia in chronic ulcerative colitis: a case controlled study. *Gastroenterology* 97,255-9 (1989)
84. A. Bedi, P.J. Pasricha, A.J. Akhtar et al. Inhibition of apoptosis during development of colorectal cancer. *Cancer Res* 55,1811-6 (1995)
85. M.P. Bronner, C Culin, J.C. Reed, E.E. Furth. The bcl-2 proto-oncogene and the gastrointestinal epithelial tumor progression model. *Am J Path* 146,20-6 (1995)
86. G. Partik, P. Kale-Rainer, R. Sedivy, A. Ellinger, W. Bursch, B. Marian. Apoptosis in human colorectal tumours: ultrastructure and quantitative studies on tissue localization and association with bak expression. *Virchow Archiv* 432,415-26 (1998)
87. T. Brown, W. Aldous, R. Lance, J. Blaser, T. Baker, W. Williard. The association between telomerase, p53, and clinical staging in colorectal cancer. *Am J Surg* 175,364-6 (1998)
88. N. Matsushashi, A. Nakajima, K. Shinohara et al. Rectal cancer after sulindac therapy for a sporadic adenomatous colonic polyp. *Am J Gastro* 93,2261-6 (1998)
89. R.T. Cormier, K.H. Hong, K.B. Halberg et al. Secretory phospholipase Pla2g2a confers resistance to intestinal tumorigenesis. *Nature Gen* 17,88-91 (1997)
90. T. Minami, S. Kanayama, H. Tojo, I. Akedo I, Y. Matsuzawa. Group II phospholipase A2 is not a major modifier of colonic adenomatous polyps in humans. *J Gastro* 32,431-2 (1997)
91. H. Kiyohara, H. Egami, G. Olaison, Y. Shibata, K. Murata, S. Oshima, M. Ogawa. Light microscopic immunohistochemical analysis of the distribution of group II phospholipase A2 in human digestive organs. *J. Histochem Cytochem* 40,1659-64 (1992)
92. T.J. Nevalainen. Serum phospholipases A2 in inflammatory disease. *Clin Chem* 39,2453-9 (1993)
93. M. Tsujii, S. Kawano, S. Tsuji, H. Sawaoka, M. Hori, R.N. DuBois. Cyclooxygenase regulates angiogenesis by colon cancer cells. *Cell* 93,705-16 (1998)
94. M.M. Entius, A.M. Westerman, F.M. Giardiello, M.L. van Velthuisen, M.M. Polak, R.J. Slebos, J.H. Wilson, S.R. Hamilton, G.J. Offerhaus. Peutz-Jeghers polyps, dysplasia, and K-ras codon 12 mutations. *Gut* 41, 320-2 (1997)
95. L. Hidalgo, A. Villanueva, T. Soler, X. Matias-Guiu, G. Capella. Molecular changes in adenocarcinoma of the small intestine associated with Peutz-Jeghers syndrome. *Rev Esp Enferm Dig* 88,137-40 (1996).

**Key words:** Oncogenesis, Adenomas, Neoplastic, Hyperplastic, Juvenile, Hamartomas

Send correspondence to: Dr M. Tobi M.B.,Ch.B., Gastroenterology Service, John D. Dingell Veterans Affairs Medical Center, 4646 John R, Detroit, MI 48201, Tel:313-576-3416, Fax:313-745-8843, E-mail:[tobim@allen-park.va.gov](mailto:tobim@allen-park.va.gov)

Received 10/ 7/98 Accepted 12/21/98