

MAGNETIC RESONANCE IMAGING (MRI) AND MAGNETIC RESONANCE SPECTROSCOPY (MRS) OF INTRACRANIAL LIPOMAS

R. Fründ, A. Geissler, M. Gliese, J. Seitz, S. Feuerbach

Rüdiger Fründ Institut für Röntgendiagnostik Klinikum der Universität Regensburg, D-93042 Regensburg Germany

TABLE OF CONTENTS

1. Abstract
2. Introduction
3. Materials and Methods
 - 3.1. Patients
 - 3.2. Methods
 - 3.3. Imaging
 - 3.4. MR Spectroscopy
 - 3.4.1. In vivo measurements
 - 3.4.2. Ex vivo measurement:
4. Results and Discussion
 - 4.1. Imaging
 - 4.2. Spectroscopy
5. References

1. ABSTRACT

We show a detailed magnetic resonance (MR) examination of two rare pericallosa lipomas with a fat suppression imaging sequence and proton MR spectroscopy. For comparison, subcutaneous fat and lipids in glioblastomas were examined with ^1H MR spectroscopy *in vivo* and *ex vivo*. Fat suppression makes the identification of lipomas simple. It is suggested that ^1H MR spectroscopy shows no differences in the aliphatic chain length of lipoma and subcutaneous fat, whereas lipids in glioblastomas have a much shorter chain length. Chain length of fatty acids in lipoma measured with *in vivo* MR spectroscopy are in concordance with data from the literature.

2. INTRODUCTION

The intracranial lipoma is a rare benign neoplasm. In an autopsy study, lipomas accounted for only 0.08 % of all brain tumors (1). Another study yielded a value of 0.1 % (2). With the introduction of computed tomography (CT), the incidence of this often symptom-free tumor increased. In a study of Kazner *et al.* (3) including 17,500 cranial CT scans, the incidence for intracranial lipomas was 0.06 % for all CT scans and 0.34% of all intracranial tumors. The widespread use of the magnetic resonance imaging (MRI) will probably further increase the incidence.

Intracranial lipomas are midline tumors. Even though the etiology of lipomas is still unknown (4), they are congenital malformations, sometimes even called lipomatous hamartomas (5).

Received 6/3/97 Accepted 9/16/97

Send correspondence to: Rüdiger Fründ, Institut für Röntgendiagnostik Klinikum der Universität Regensburg, D-93042 Regensburg Germany, Tel: 0049 941 944 7407, Fax:0049 941 944 7402, E-mail: ruediger.fruend@ klinik.uni -regensburg.de

They possibly originate from meninx primitiva (6). Pericallosa lipomas are often associated with other developmental malformations such as partial or complete agenesis of corpus callosum (7).

Fatty tissue can be easily identified with MRI if sequences with fat suppression are used. Magnetic resonance spectroscopy (MRS) allows even more specific identification of fatty tissue especially lipids. MRS offers insights on the structure of lipids present in lipomas, malignant tumors and normal fat and allows detection of structural differences.

3. MATERIALS AND METHODS

3.1. Patients:

Patient A was an 18 year old woman with headache. No biopsy was performed. Patient B was a 50 year old man. The only clinical symptom was a non stable heel to toe gait. Surgical biopsy was performed. Both patients had no abnormal cerebral liquor circulation. Four patients (1 female, 3 males, ages 58 to 73 years) with histologically verified glioblastomas grade IV (WHO) and high levels of fat signals, detected by MRS, were evaluated for the glioblastoma group. Subcutaneous fat was measured in the neck of a healthy, 35 year old man. Intraoperatively collected biopsy specimens were immediately frozen in liquid nitrogen. Normal subcutaneous fat sample was collected from the back of a person with no known disturbance in the metabolism during intervertebral disc surgery.

3.2. Methods:

For all *in vivo* examinations, a 1.5 T Magnetom SP 63 (Siemens, Erlangen, Germany) with a CP-headcoil was used.

3.3. Imaging:

T1 weighted MR-images were acquired with spinecho technique (TR = 570 ms, TE = 15 ms) in axial or sagittal orientation. Slice thickness was 6 mm with a

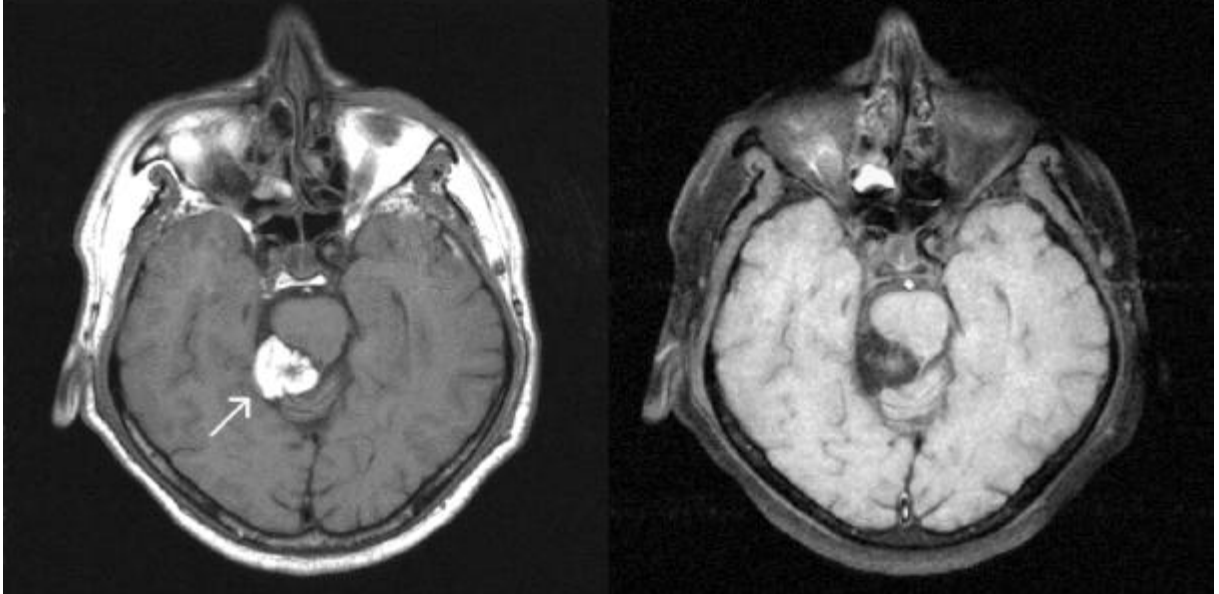


Figure 1: Axial T1 weighted brain images of patient A . Left without fat suppression, right with fat suppression, arrow indicates lipoma.

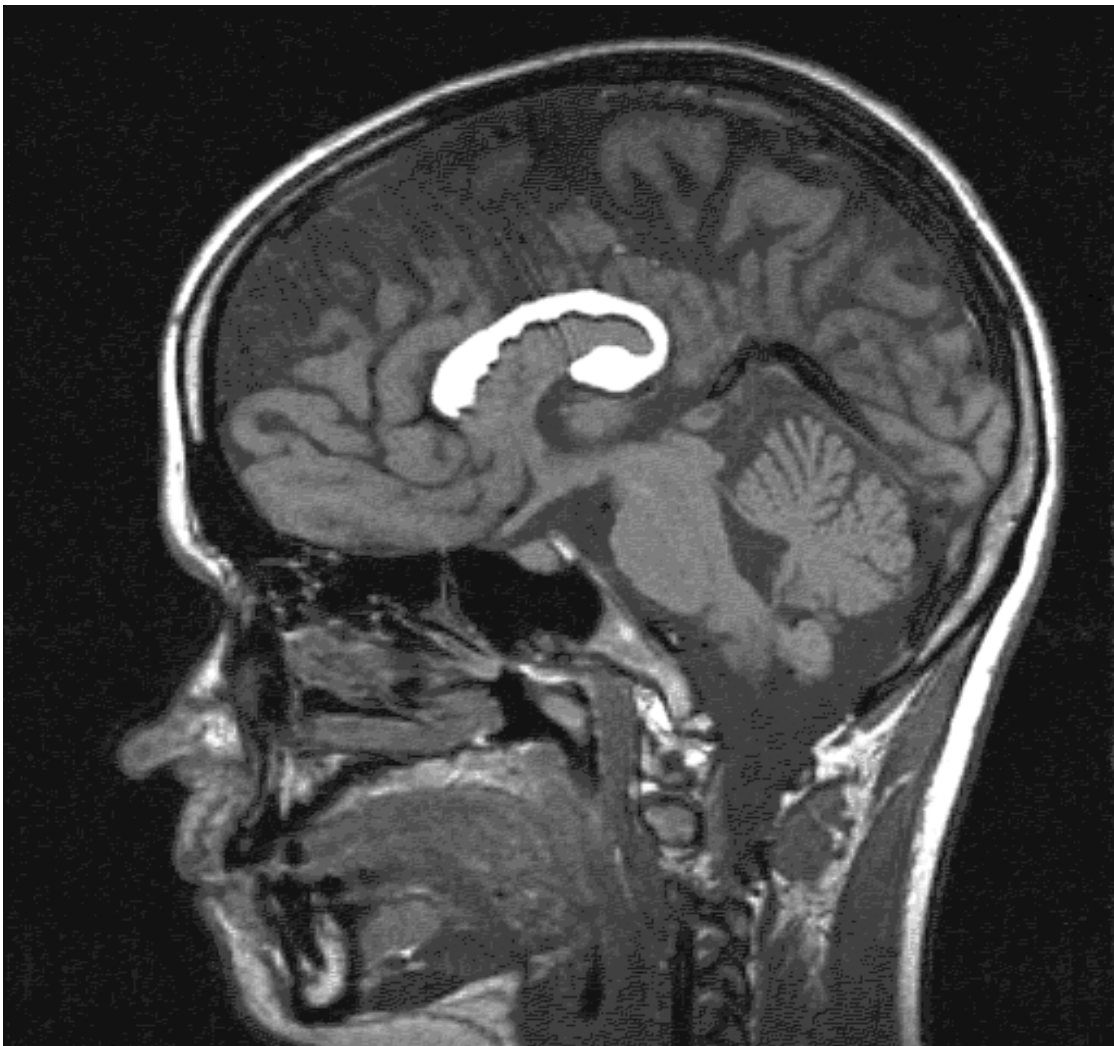

Figure 2: Sagittal T1 weighted brain images of patient B without fat suppression.

Table 1: *In vivo* and *ex vivo* integral ratios of the values from the signals at 1.3 ppm and 0.9 ppm.

	Ratio of signal intensity at 1.3 ppm vs. 0.9 ppm <i>ex vivo</i>	Ratio of signal intensity at 1.3 ppm vs. 0.9 ppm <i>in vivo</i>
Lipoma A	-	5.4:1
Lipoma B	6.6:1	6.7:1
Glioblastomas	2.9:1	2.2:1
subcutaneous fat	6.5:1	5:1

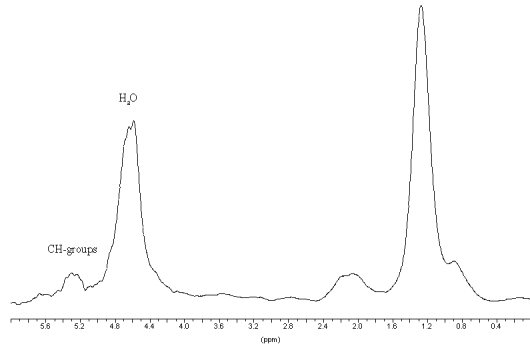


Figure 3: *Ex vivo* (A) and *in vivo* (B) ¹H spectra from lipoma B, *In vivo* ¹H spectra from subcutaneous fat (C) and glioblastoma grad IV (D). Signal height is calibrated to the resonance at 1.3 ppm.

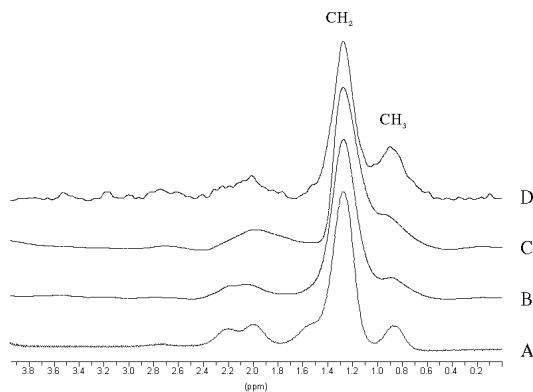


Figure 4: *In vivo* ¹H-spectrum from lipoma B without water suppression. CH-groups of unsaturated hydrocarbon chains are visible at 5.3 ppm.

20 % gap. 19 slices were acquired. Fat suppression was performed by a spectral saturation pre-pulse.

3.4. MR Spectroscopy:

3.4.1. *In vivo* measurements:

A stimulated echo sequence (STEAM) with 20 ms echotime, 30 ms mixing time and 1.5 s repetition time was used. Voxel size was 15x15x15 mm. 256 acquisitions with 1k points were accumulated. FIDs were eddy-current compensated with a commercially available software using a reference scan without water suppression (8). Data were transferred to an external PC, zero-filled to 16 k points, fourier transformed, phase and baseline corrected. The resonances were Gauss

fitted and integrated. T1 and T2 relaxation times were not considered.

3.4.2. *Ex vivo* measurement:

Biopsy samples were analyzed in D₂O at 7 Tesla with a Bruker (Karlsruhe, Germany) MSL 300 spectrometer in a 5 mm ¹H-probehead at room temperature. A simple 90 degree pulse acquisition program with pre-irradiation of the residual water peak was used. Repetition time was set to 10 s. 128 acquisitions with 8 k points were accumulated. Postprocessing was made in the same manner as the *in vivo* data.

4. RESULTS AND DISCUSSION

4.1. Imaging

Figures 1 and 2 show a T1 weighted image of patient A with and without fat suppression. MR-imaging using fat suppression pre-pulses results in good signal extinction for the orbital region, subcutaneous fat and the lipoma in the area of the brain stem. Therefore lipomas can be easily detected. In addition fibrotic tissue and vascular structure of the lipoma can be seen in more detail with fat suppression for intracranial lipomas. Similar attempts with good results were made for tumors of the adrenal gland in order to distinguish benign fat tissue from malignant tissue (9). For the cases described here, the method can be used for a specific diagnosis of the tumor. This is most helpful in the differential diagnosis of fat, small amounts of blood and small lipomas.

4.2. Spectroscopy

Voxels placed in the lipoma showed strong signals at 2.15, 1.3 and 0.9 ppm (Figure 3). The signal at 1.3 ppm can be assigned to CH₂ groups in long alkyl chains. The resonance at 0.9 ppm stems from CH₃ groups of these chains. The broad signal around 2.15 ppm can be assigned to CH₂ groups in the neighbourhood of unsaturated CH-groups and to CH₂-groups next to the carboxygroup in carbonic acid. Due to the slightly better resolution of the *ex vivo* spectra, an additional peak at 1.6 ppm is visible. In the spectrum without water suppression the CH=CH groups of unsaturated carbonic acids was resonating at 5.3 ppm (Figure 4). No signals of normal human brain metabolites (10) like N-acetylaspartat, choline, creatine or myo-inositol were detected. The *in vivo* measurements of normal subcutaneous fat did not differ from intracranial lipomas. However, lipid signals often seen in high grade glioblastomas had lower CH₂ to CH₃ intensity ratios. The *ex vivo* measurements differs not significantly from the *in vivo* measurements. Only the resolution is slightly better for the *ex vivo* measurements. In table 1, the ratios for the signal intensities at 1.3 and 0.9 ppm of different tissues are shown.

In contrast to MR-imaging, MR-spectroscopy gave more detailed information about the chemical

Characterisation of lipids in lipomas, subcutaneous fat and gliomas with magnetic resonance

composition of the examined tissues. Lipids in human adipose tissue mainly consist of tri-acylglycerol. The most frequent fatty acids are oleic acid (39 %), palmitic acid (26 %) and linoleic acids (15%) (11). MR-spectroscopy can determine the amount of CH₃ and CH₂ groups in these fatty acids (12). Methyl groups at the end of the fatty acids chain induce a shift of 0.9 parts per million (ppm). Methylene groups in the middle of the chain introduce a shift at 1.3 ppm (12). The ratios of the peak areas indicate the length of saturated alkyl chain. Table 1 shows similar ratios for the two lipomas and for the subcutaneous fat. Therefore, the length of the chain of fatty acids in lipomas and subcutaneous fat must be in the same range and should be structurally similar. The calculated theoretical ratio of intensities for the signals at 1.3 ppm and 0.9 ppm of olefinic acid is 6.7:1 because only 10 CH₂ groups have a resonance around 1.3 ppm. The other CH₂ groups are either in the vicinity of the carboxy group resulting in a resonance frequency of 2.36 ppm for the closest CH₂ group and 1.65 ppm for the following CH₂ group or 2.07 ppm in the neighbourhood of the ethylene group (12). This calculated ratio is very close to the measured value of lipoma from patient B and within the limits of measurements for lipoma from patient A and the subcutaneous fat.

In comparison, the ratios found for glioblastomas are much smaller, indicating shorter hydro-carbon chains for the lipid-like substances in tumor tissues. If all these substances consist of saturated fatty acids, the MR-data suggest a C8:0 type. The reduced linewidth found for the lipid resonances in glioblastomas support the idea of a shorter alkyl chain length in these tissues due to a higher mobility of molecules.

The unsaturated parts of the chains are visible in the *in vivo* spectra of lipomas and fat tissue acquired without water suppression. Figure 4 shows an extra resonance at 5.3 ppm originating from unsaturated parts of the chains (12, 13).

Our *ex vivo* data confirm the *in vivo* results (Table 1). Taking into account the long repetition time and the missing echo time, the *ex vivo* values were not effected by T1 and T2, suggesting that the *in vivo* ratios were not influenced by this two relaxation times either.

MRS allows the *in vivo* evaluation of the structure of intracerebral lipoma tissue and may be helpful for the differentiation of benign and malignant tumors.

5. REFERENCES

1. AR. Vonderahe & WT. Niemer: Intracranial lipoma: A report of four cases. *J Neuropathol Exp Neurol* 3, 344-354 (1944).

2. JE. Wilberger, A. Abla & W. Rothfus: Lipoma of the septum pellucidum: case report. *J Comput Assist Tomogr* 11, 79-82 (1987)

3. E. Kazner, O. Stockdorph, S. Wende & T. Grumme: Intracranial lipoma: diagnosis and therapeutic considerations. *J Neurosurg* 52, 234-245 (1980)

4. PM. Britt, AK. Bindal, MG. Balko & HS. Yen: Lipoma of the Cerebral Cortex: Case Report *Acta Neurochir (Wien)* 121, 88-92 (1993)

5. H. Budka: Intracranial lipomatous hamartomas (intracranial 'lipomas'): A study of 13 cases. *Acta Neuropath (Berl)* 28, 205-222 (1974)

6. CL. Truwit & AJ. Barkovich: Pathogenesis of intracranial lipoma: An MR study in 42 patients. *AJNR* 11, 665-674 (1990)

7. RP. Tart & RG. Quisling: Curvilinear and tubulonodular varieties of lipoma of the corpus callosum: An MR and CT study. *J Comput Assist Tomogr* 15, 805-810 (1991)

8. RJ. Ordidge & ID. Cresshall: The correction of transient B₀ field shifts following the application of pulse gradients by phase correction in the time domain. *J Magn Reson* 69, 151-155 (1986)

9. DG. Mitchell, M. Crovello, T. Matteucci, RO. Petersen & MM. Miettinen: Benign adreno-cortical masses: diagnosis with chemical shift MR imaging *Radiology* 185, 345-351 (1992)

10. T. Michaelis, KD. Merbolt, W. Hanicke, ML. Gyngell, H. Bruhn & J. Fram: On the identification of cerebral metabolites in localized ¹H NMR spectra of human brain *in vivo*. *NMR Biomed* 4, 90-98 (1991)

11. KJ. Halliwell, BA Fielding, JS Samra, SM. Humphreys & KN. Frayn: Release of individual fatty acids from human adipose tissue *in vivo* after an overnight fast. *J Lipid Res* 37, 1842-1848 (1992)

12. S. Singer, M. Sivarja, K. Souza, K. Millis & JM. Corson: ¹H-NMR detectable fatty acyl chain unsaturation in excised leiomyosarcoma correlate with grade and mitotic activity. *J Clin Invest* 98, 244-250 (1996)

13. L. Le Moyec, R. Tatoud, M. Eugene, C. Gauville, I. Primot, D. Charlemagne & F. Calvo: Cell and membrane lipid analysis by proton magnetic resonance spectroscopy in five breast cancer cell lines. *Br J Cancer* 66, 623-628 (1992)