

SONOHYSTEROGRAPHIC IMAGING OF THE ENDOMETRIAL CAVITY

A Parsons¹, A Hill, and D Spicer

University of South Florida, 4 Columbia Drive, Tampa, FL 33606

TABLE OF CONTENTS

1. Abstract
2. Introduction
3. Materials and methods
4. Results and discussion
5. References

1. ABSTRACT

Vaginal ultrasound is the most effective method of imaging the contents of the true pelvis in the female. Saline infusion sonohysterography (SIS) is a simple refinement of the standard vaginal sonographic exam. Here, we briefly describe and demonstrate our use of this latter technique.

2. INTRODUCTION

Hysterosalpingography is a radiographic technique which has been used for over 70 years for the examination of the uterine cavity. However, this technique requires pelvic irradiation and a radiological imaging suite. In addition the contrast medium used is highly irritating. On the other hand, ultrasound at imaging frequencies is biologically innocuous. In addition, the equipment is portable and inexpensive and the contrast medium which is used is sterile normal saline. Frequencies of between 5 and 9 MHz allow axial resolution of 1 mm or less. SIS provides details of soft tissue structures as well as of the shape of the uterine cavity. This technique allows detailed study of the uterine cavity in cases of abnormal uterine bleeding, amenorrhea, uterine anomalies and inadequate or abnormal endometrial images (1-5).

3. MATERIALS AND METHOD

Catheters: For patulous cervixes or enlarged uteri, the 2 mm H/S catheter with a 3cc balloon (Ackrad Co., Cranford, New Jersey) was used. This is a standard hysterosalpingogram catheter. For distension of normal sized uteri a straight 2.3 mm catheter such as the Soules intrauterine insemination (IUI) catheter (Cook company, Spencer, Indiana) was

used (1). In some occasions, a 38 cm, 1.6 mm in diameter, premature infant feeding tube (#3640, Davol Cranston, RI) was also used (2). These fine straight catheters allowed almost painless uterine distention because they permitted leakage of saline from the cervix. The vaginal probe which was used was the C9-5, Ultramark 9, HDI, Advanced Technology Laboratories, Bothell, Washington

All vaginal scans were performed with the patient in stirrups on a gynecological exam table with a pull-out basin. The bladder was empty. Patients in whom PID was suspected were treated before this procedure. For obtaining the baseline scan the vaginal probe was protected with a condom and inserted into the anterior fornix of the vagina as depicted in Fig 1. First the uterus was imaged. Then, the mid-sagittal plane was identified by imaging the endometrial cavity and the entire length of the cervical canal. The ultrasound probe was perpendicular to the uterine axis for the best resolution of the endometrium. In order to examine the endometrium for asymmetry and abnormal contours, the uterus was scanned from cornu to cornu. The transducer was then rotated 45 degrees and the uterus was scanned from the external cervical os to the fundus in a transverse orientation. The thickness, hormone effect (echogenic pattern) and shape of the endometrium were noted. In order to do SIS, the cervix was cleansed through a speculum. A catheter was inserted into the cervix with packing forceps. The IUI catheter was advanced all the way to the fundus (Fig 1). When using the H/S catheter, the balloon was placed in mid cervix and gently inflated with 1 to 2cc of saline (not air). A 10 to 60cc syringe with IV injectable grade normal saline was attached to the catheter and the saline was slowly infused while scanning the uterus systematically in the sagittal and then transverse planes in order to delineate the contours of the entire cavity. Both uterotubal ostia were identified to confirm the shape of the cavity.

Received 7/27/95; Accepted 8/12/95

¹ To whom correspondence should be addressed, at University of South Florida, 4 Columbia Drive, Tampa, FL 33606

Sonohysterographic imaging

4. RESULTS AND DISCUSSION

In order to examine the specificity and sensitivity of SIS, we performed this procedure on 53 women who were scheduled for hysterectomy. The indication for the surgery included intractable abnormal uterine bleeding, endometrial hyperplasia,

Figures

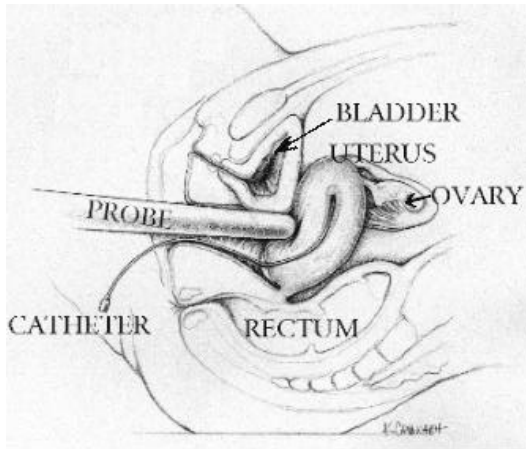


Fig 1 legend: Schematic representation of the sonohysterography. For obtaining the best image resolution, the vaginal probe is in contact through the vaginal wall with the uterus. The tip of the straight catheter is placed in the fundus.

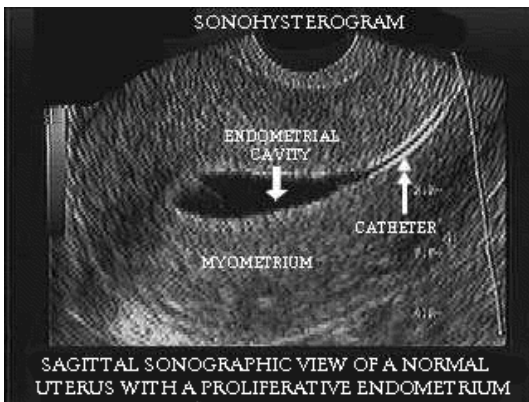


Fig 2 legend: Sagittal sonographic view of normal uterus with early proliferative endometrium. Sonohysterogram was obtained in a uterus with early proliferative endometrium by distension of the endometrial cavity by inserting a catheter within the cavity and instillation of 2 cc of sterile normal saline. Note the catheter in the cervix. The tip of the catheter at the fundus is not imaged.

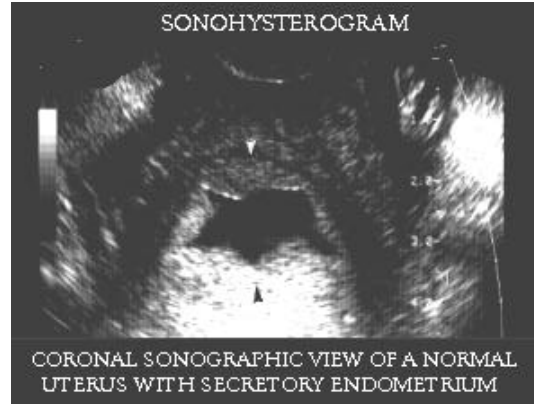


Fig 3 legend: Coronal sonographic view of normal uterus with secretory endometrium. The sonohysterogram was obtained as indicated in Fig 2 legend. The arrowheads point to the basal part of the endometrium.

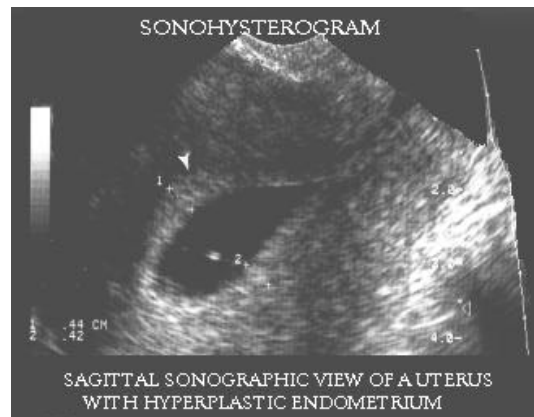

Fig 4 legend: Sagittal sonographic view of a uterus with hyperplastic endometrium. The sonohysterogram was obtained as indicated in Fig 2 legend. The arrowhead points to the basal part of the endometrium. The thickness of the endometrium measured at two points and marked as 1 and 2 are respectively 0.44 and 0.42 cm. The diagnosis was established by histologic evaluation of the endometrial tissue.

Sonohysterographic imaging

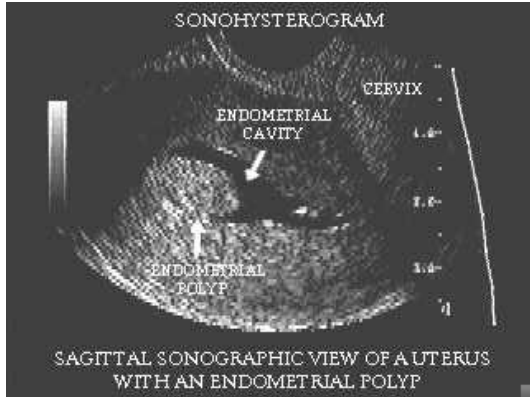


Fig 5 legend: Sagittal sonographic view of a uterus with an endometrial polyp. The arrow points to a 12 mm fundal endometrial olyp in an otherwise atrophic endometrium.

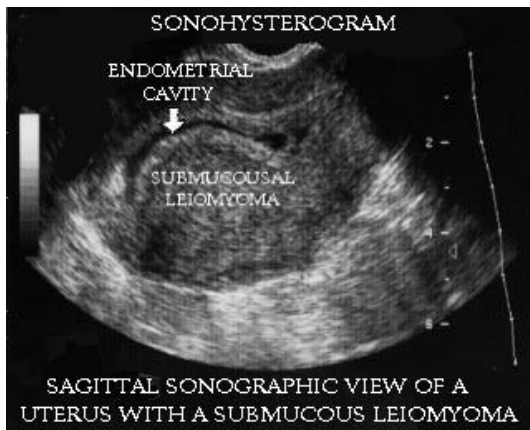


Fig 6 legend: Sagittal sonographic view of a uterus with a submucous leiomyoma. The leiomyoma is protruding into the endometrial cavity.

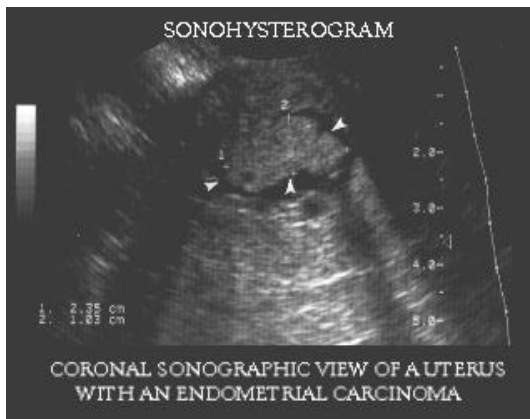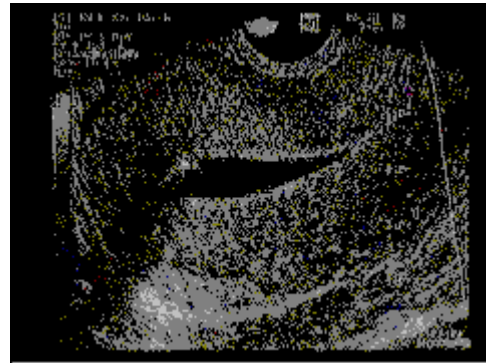


Fig 7 legend: Coronal sonographic view of a uterus with an endometrial carcinoma. Arrowheads point to the boundaries of the endometrial carcinoma protruding from the anterior wall into the endometrial

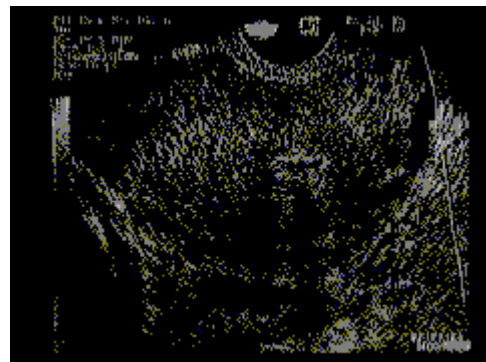
cavity. The dimensions of the lesion were measured as 2.35 and 1.03 cm.

Videos

For information on viewing, see the on-line documentation

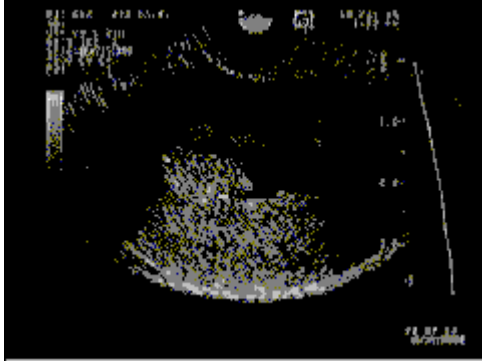


Video 1 legend: Sagittal maneuver for the systematic sonographic demonstration of the endometrial cavity. The cavity in this normal uterus with an early proliferative endometrium is surveyed from cornu to cornu while infusing normal saline rendering a three dimensional impression of the endometrial cavity contour (Quicktime movie; 1,103,050 bytes).

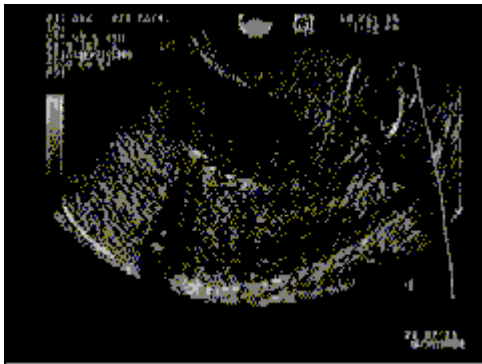


Video 2 legend: Transverse scanning maneuver for the systematic sonographic demonstration of the endometrial cavity. The cavity in this uterus with early proliferative endometrium is surveyed from exocervix to fundus while infusing normal saline rendering a three dimensional impression of the endometrial cavity contour (Quicktime movie; 909,378 bytes).

Sonohysterographic imaging



Video 3 legend: Sagittal maneuver for the systematic sonographic demonstration of an endometrial polyp. The endometrial cavity is surveyed from cornu to cornu to locate an endometrial polyp protruding into the endometrial cavity from the right-posterior wall of the fundus. The hyperechoic polyp is marked by arrow in Fig 5 (Quicktime movie; 497,133 bytes).



Video 4 legend: Transverse maneuver for the sonographic identification and localization of an endometrial polyp. The smooth hyperechoic polyp is seen in the right cornu as the uterus is scanned from the exocervix to the fundus (Quicktime movie; 631473 bytes).

Note: For instruction on viewing videos, please see the on-line documentation.

painful pelvic adhesions, uterine myomata, persistent high grade CIN and endometrial cancer. SIS was used for the diagnosis and localization of the lesions within and outside the endometrial cavity. No procedure required interruption of the SIS due to pain. The cavity could be visualized in all cases. The follow up after SIS revealed no sequelae. In this selected series, of all the cases, 95 % of lesions were correctly identified. The diagnoses rendered after evaluation of the endometrial cavity by SIS and which were established after surgery by pathologic examination of the hysterectomy specimen included isolated submucous leiomyoma (n=6), single endometrial polyp (n=4), multiple endometrial polyps (n=3),

submucous leiomyoma along with endometrial polyp (n=6), endometrial carcinoma (n=3), endometrial hyperplasia (n=1) and normal endometrial cavity (n=31) (Fig 2-6, Video 1-4). The cases with normal endometrial cavities were lined by proliferative or secretory endometrium. The case not diagnosed by the SIS was a single 3 mm cornual polyp in a case with multiple endometrial polyps. Thus, similar to that reported previously (5-6), the sensitivity and specificity of the procedure in this series are respectively 95% and 100%.

The diagnosis of the lesions was facilitated by the presence of fluid within endometrial cavity. Polyps were invariably hyperechoic relative to the surrounding tissues and sometimes contained small cavitations. Intracavitary and submucous leiomyomata were hypoechoic. However, similar to endometrial polyps some of the leiomyomas that were smaller than 1 cm in diameter appeared hyperechoic. Whereas polyps and the case of hyperplasia did not alter the basalis-myometrial interface, the myomata and invasive cancer were characterized by the disruption of this interface.

In summary, sonohysterography in view of its high specificity and sensitivity, may replace diagnostic hysteroscopy. However, accurate diagnosis of the endometrial abnormalities and distinction of hyperplasias from disordered endometrial proliferation and endometrial cancer still requires histologic evaluation of the endometrial tissue.

5. REFERENCES

1. Parsons AK, Lense J: Sonohysterography for endometrial abnormalities: Preliminary results. *J Clin Ultrasound* 21, 87-95, 1993
2. Cullinan JA, Fleischer AC, Kepple DM, Arnold AL: Sonohysterography: A technique for endometrial evaluation. *Radiographics* 15, 501-514, 1995.
3. Bonilla-Musoles F, Simon C, Serra V, Sampaio M, Pellicer A: An assesment of hysterosalpingo-sonography (HSSG) as a diagnostic tool for uterine cavity defects in tubal patency. *J Clin Ultrasound* 20, 175-181, 1992
4. Goldstein SR: Use of ultrasonohysterography for triage of perimenopausal patients with unexplained uterine bleeding. *Am J Obstet Gynecol* 170, 565-570, 1994
5. Randolph JR, Ying YK, Maier DB, Schmidt CL, Riddick KH: Comparison of real-time ultrasonography, hysertosalpingography and laparoscopy/hysteroscopy in the evaluation of the

Sonohysterographic imaging

uterine abnormalities and tubal patency. *Fertil Steril* 6, 828-832, 1986

6. Mitri FF, Andronikou AD, Perpinyal S, Hofmeyer GJ, Sonnendecker EW: Clinical comparison of sonographic hydrotubation and hysterosalpingography. *Br J Obstet Gynecol* 98, 1031-1036, 1991