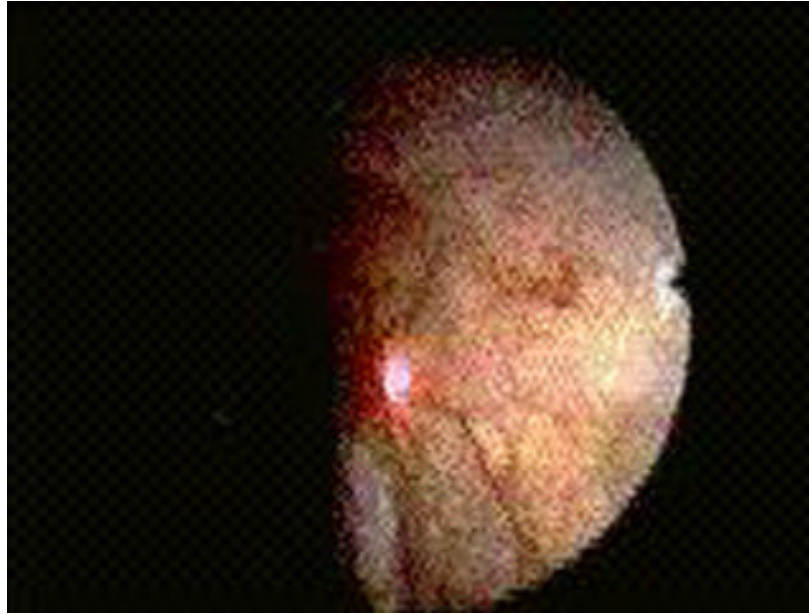


THE ROLE OF LAPAROSCOPY IN THE DIAGNOSIS OF GYNECOLOGIC PATHOLOGIES

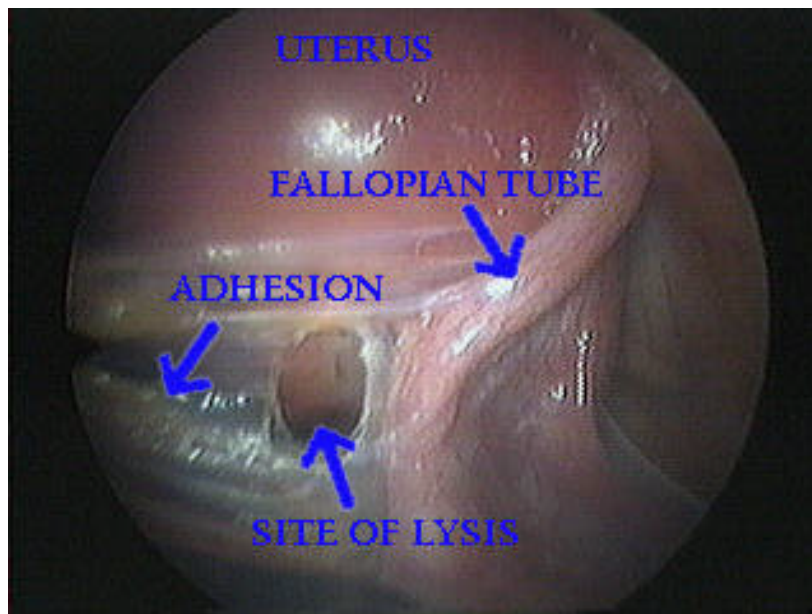
A Babaknia

Women's Health Institute of California, 1 San Sebastian, New Port Beach, CA 92660

Received 08/01/95; Accepted 08/15/95

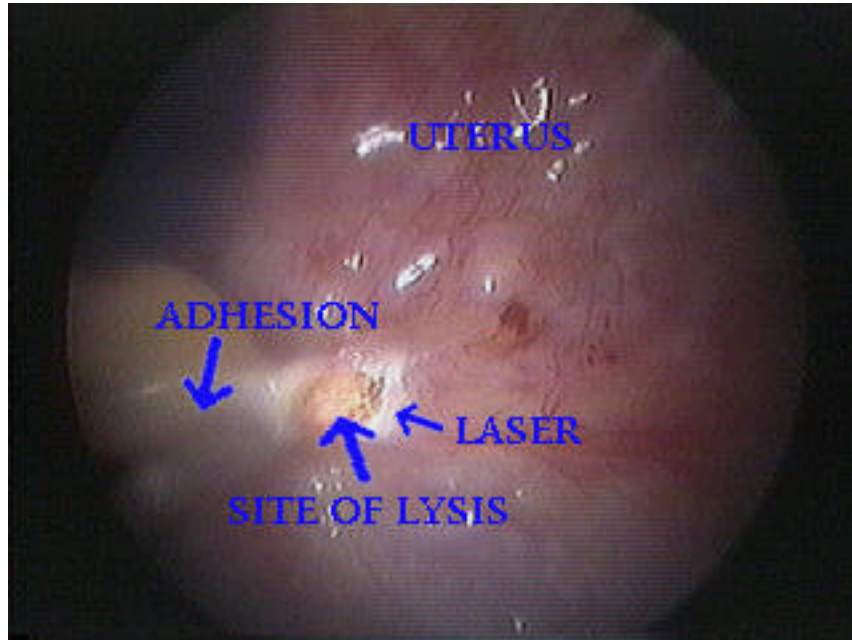


Video legend: Laparoscopic appearance of the neon laser. The CO₂ laser is not visible to the human eye. Therefore, the neon laser is used to localize the CO₂ laser. Neon laser is seen as a bright red beam. (Quicktime movie:330 Kb)

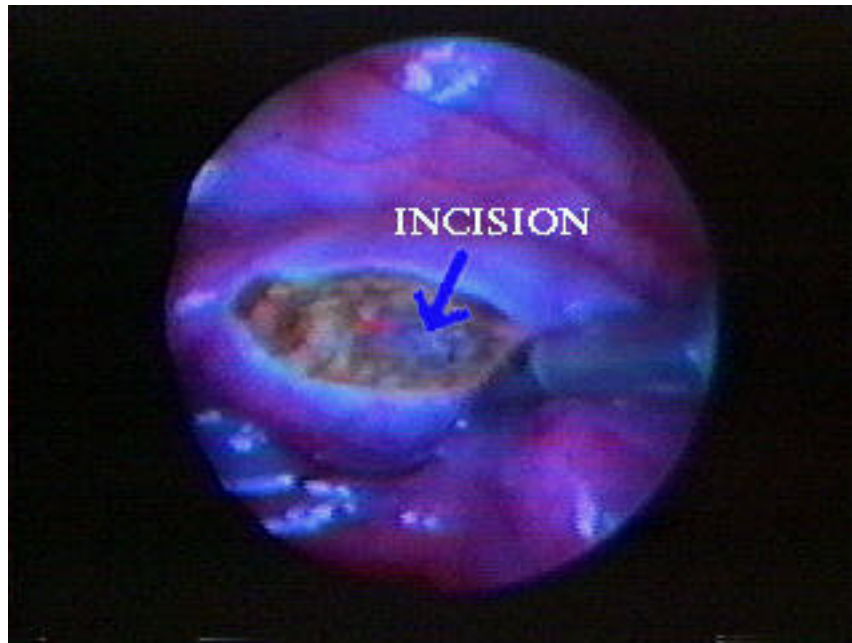

Video legend: Laparoscopic view of the CO₂ laser lysis of peritubal adhesion. The video segment initially shows the peritubal adhesion. Subsequent frames show the lysis of the adhesions by CO₂ laser. (Quicktime movie:798 Kb)

Laparoscopy in gynecologic diagnosis



Video legend: Laparoscopic view of the CO₂ laser lysis of the uterine adhesion. The video segment initially shows the uterine adhesion. Subsequent frames show the lysis of the adhesion by CO₂ laser. (Quicktime movie:1.04 Mb)



Video legend: Laparoscopic view of CO₂ laser treatment of tubal pregnancy. Initially, the segment of fallopian tube with ectopic pregnancy is visualized. Subsequently, a longitudinal incision is made along the fallopian tube by the CO₂ laser beam. Then, the products of conception are removed from the fallopian tube (the tubal pregnancies can not lead to a viable delivery. If not treated in a timely manner, ectopic pregnancy is a serious medical condition that is potentially fatal). The video segment finally demonstrates the incision site. (Quicktime movie:990 Kb)

Note: For instruction on viewing videos, please see the on-line documentation